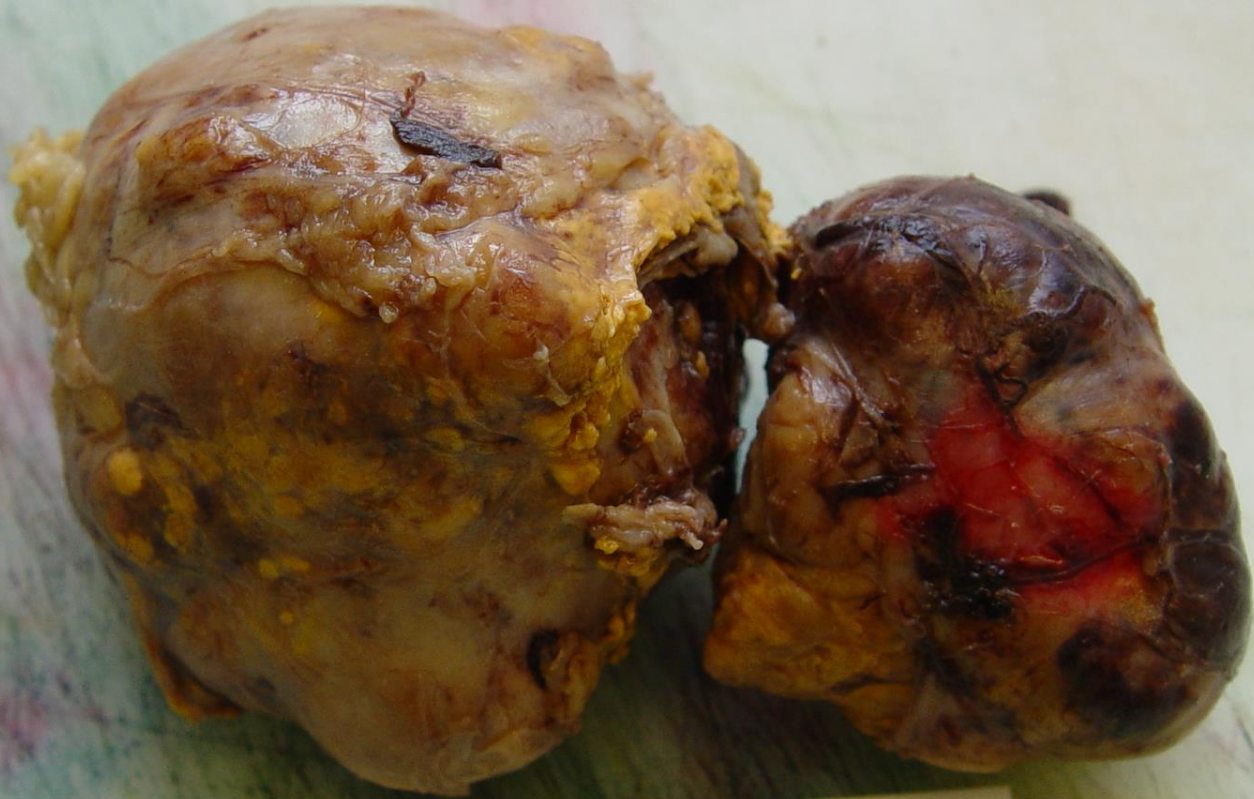


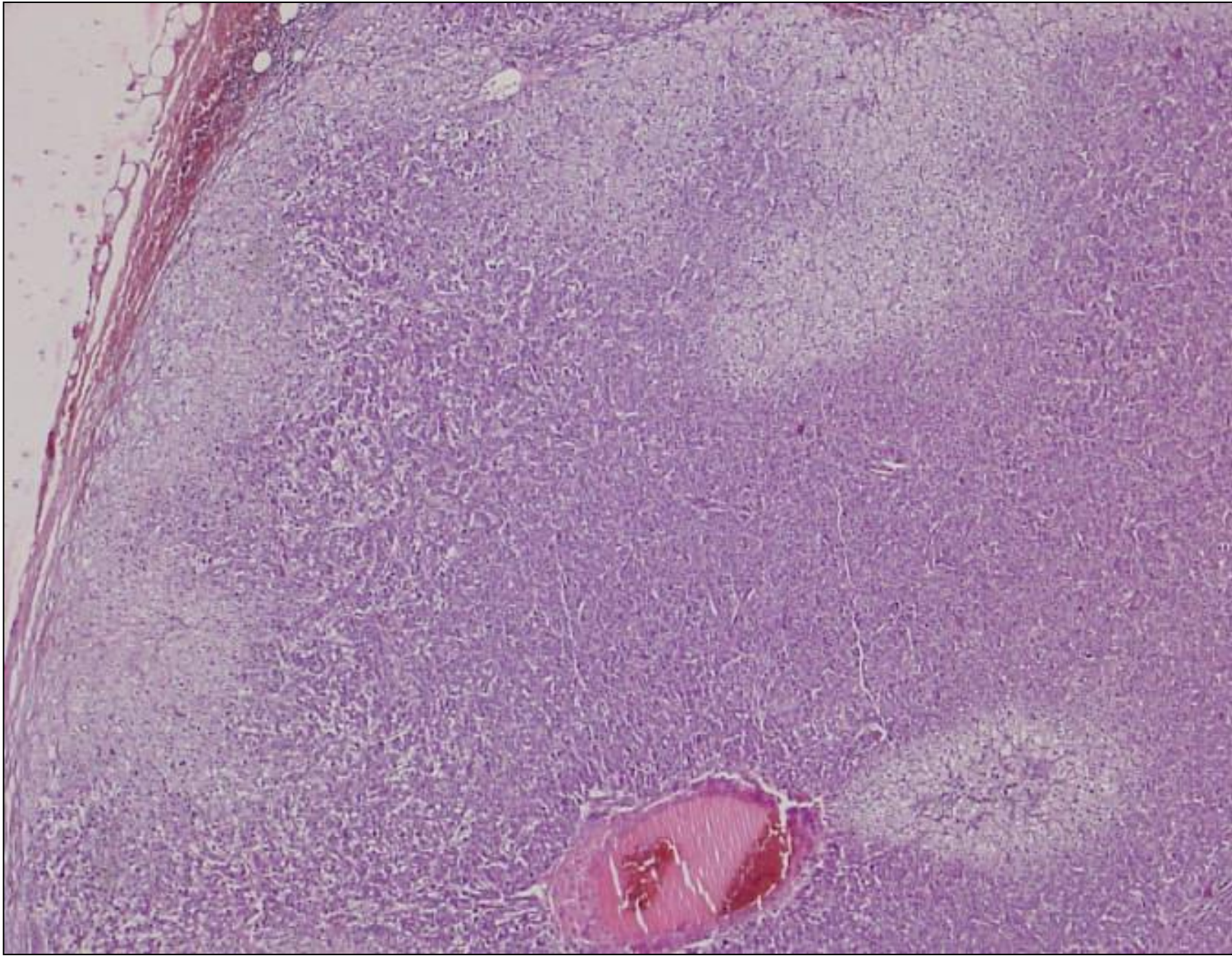
Nebennierenrindencarzinom

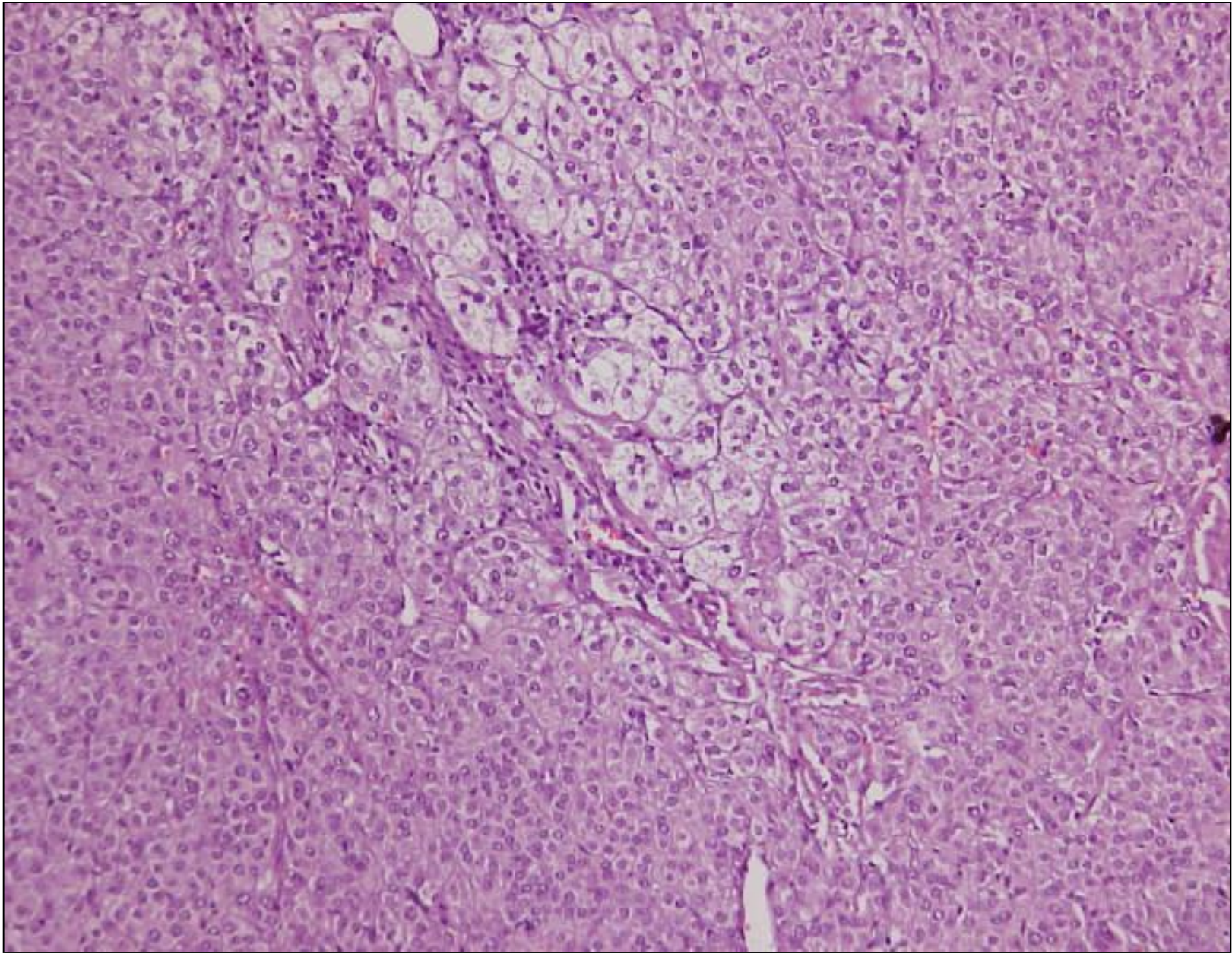
Falldemonstration männlich 48 Jahre alt

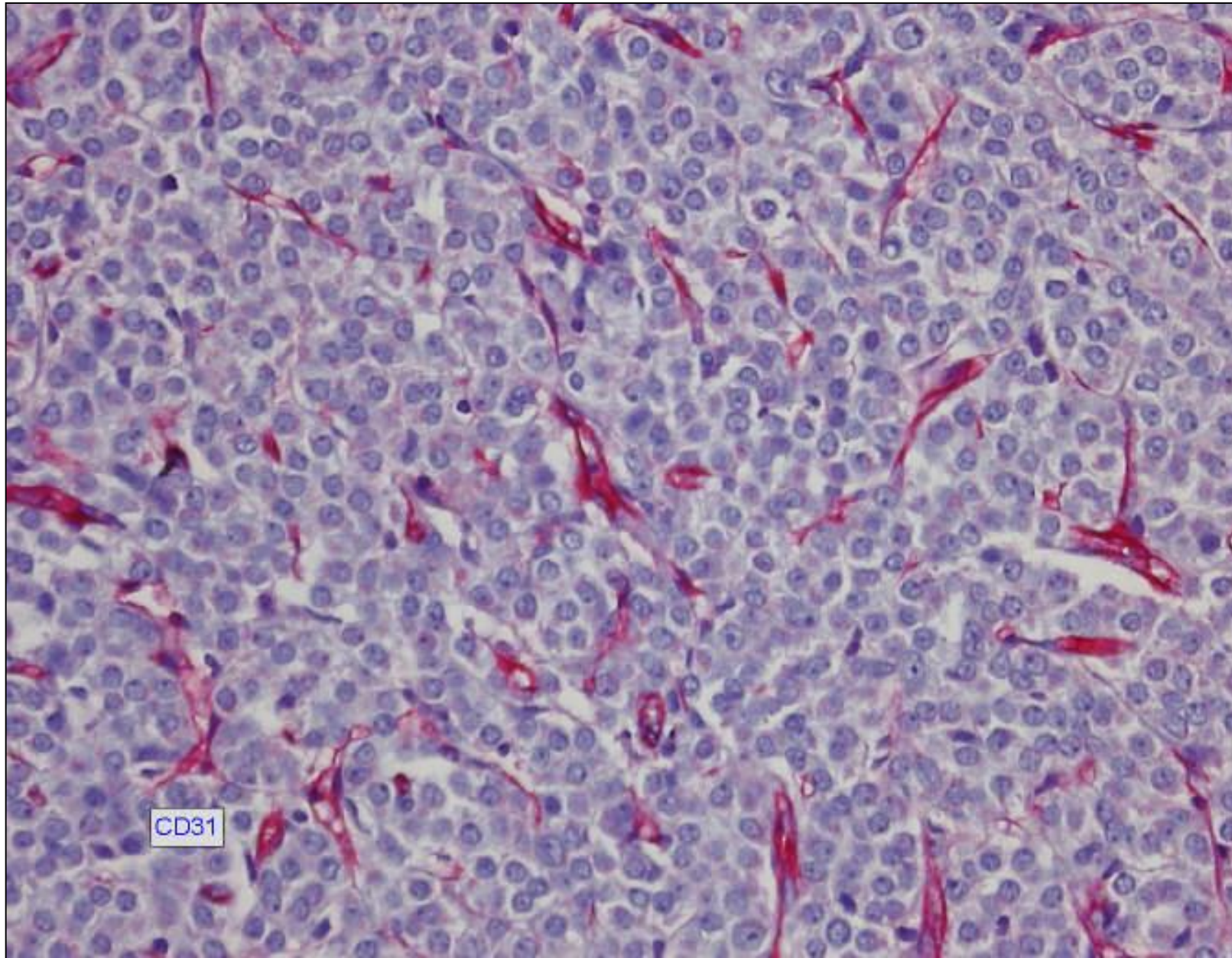
- Nebennierenrindencarzinom
- Ältere Fettgewebsnekrose bei V.a. Zustand nach Pankreatitis

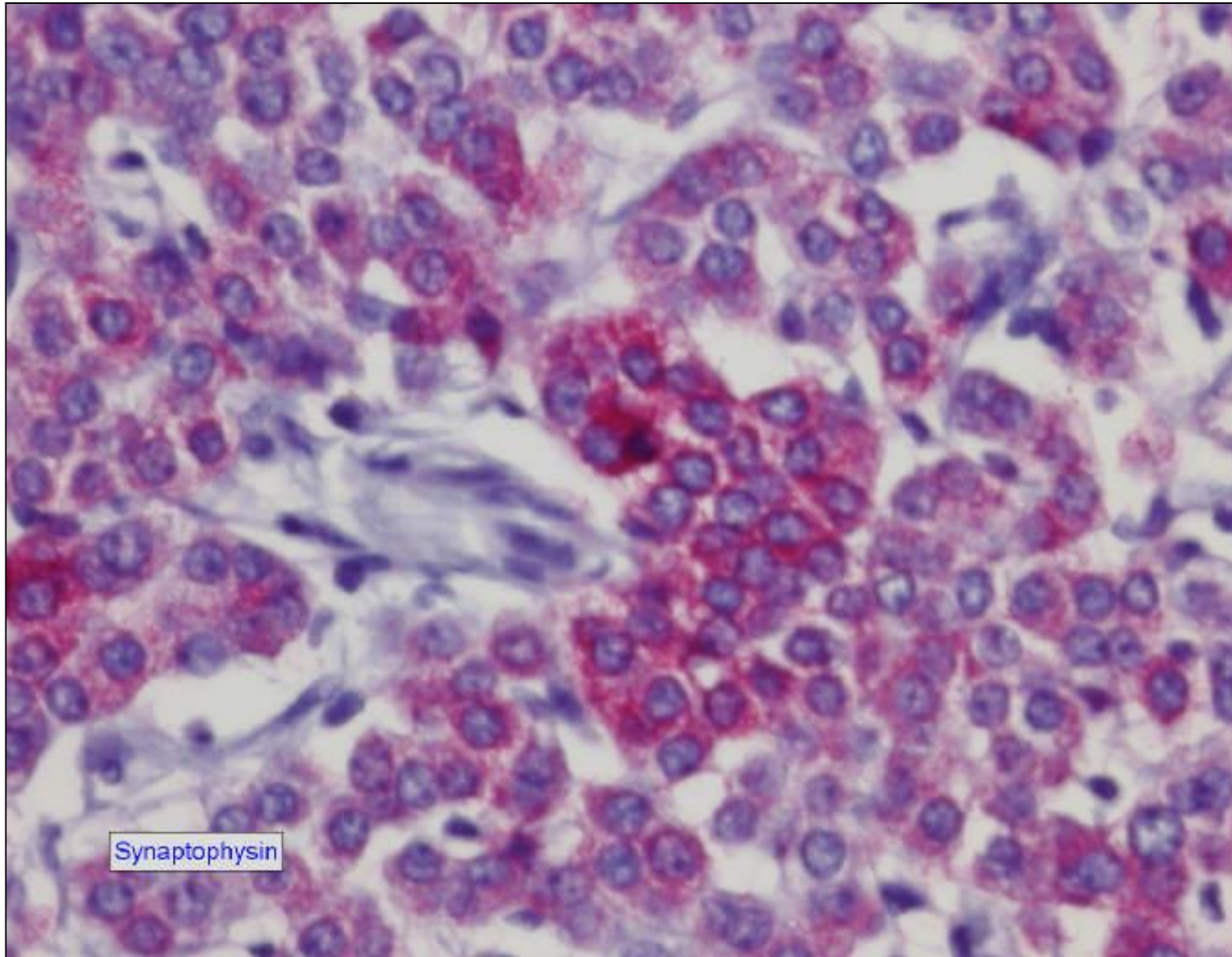


11 10:14 AM



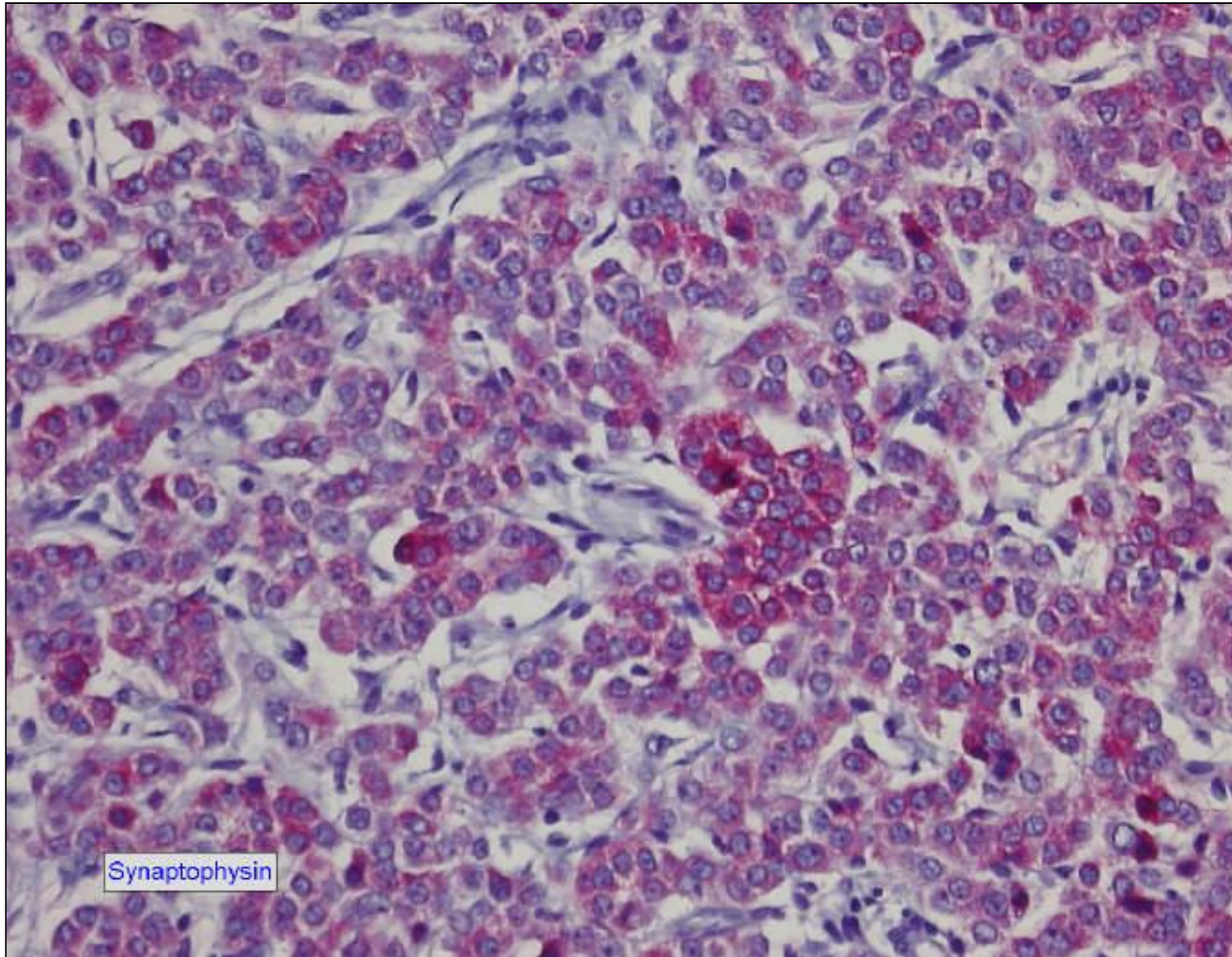






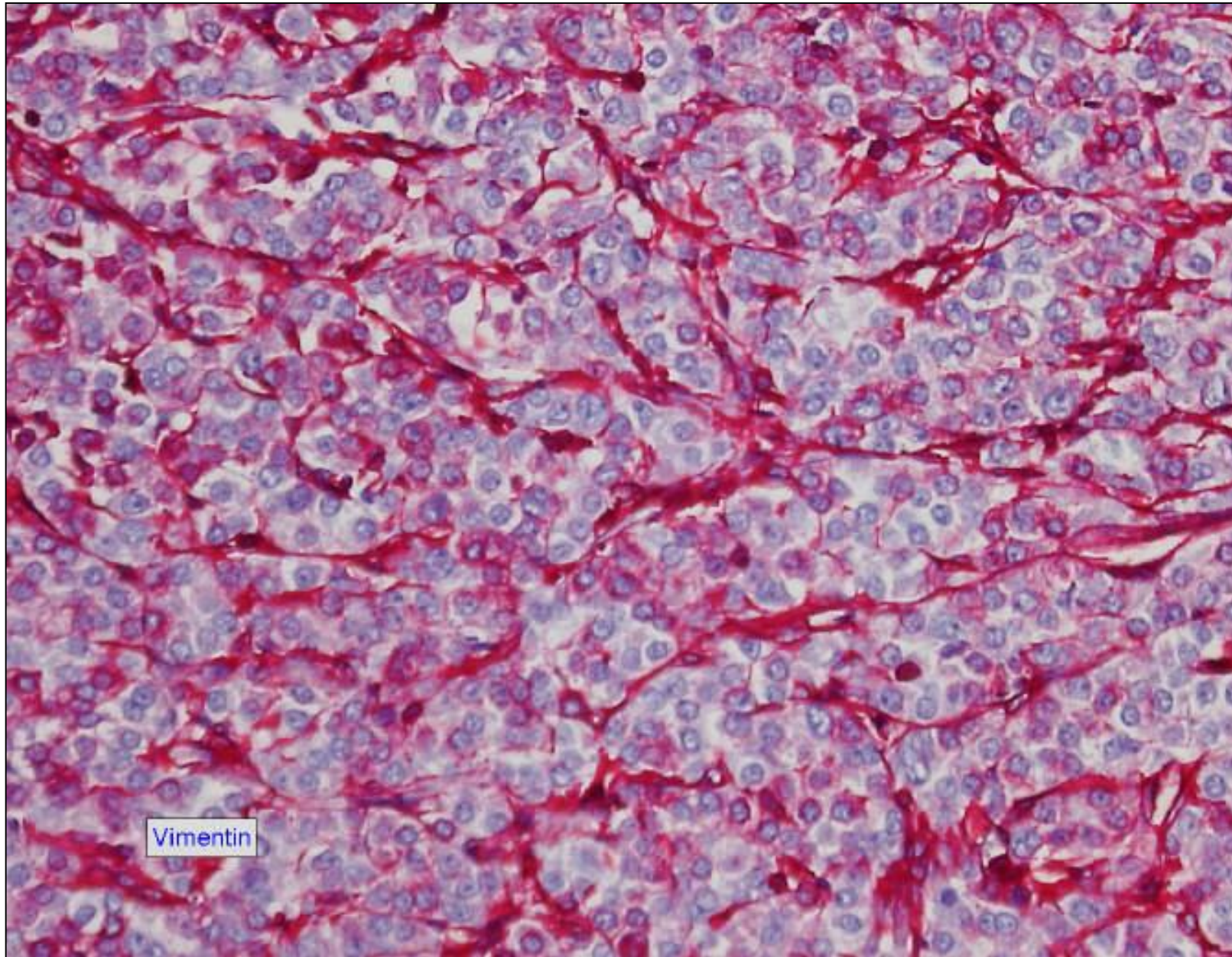
Synaptophysin





Synaptophysin





Vimentin



Nebennierenkarzinome

- 1/1.000.000 Einwohner (USA)
- Vorkommen in allen Altersgruppen jedoch :
- Erwachsenenalter (5.-6. Dez.)
- Kindesalter sehr selten
- weiblich : männlich = 1.5 : 1 (unterschiedliche Statistiken)
- linke NN > rechte NN (52.8 : 47.2 %)
- Zum Zeitpunkt der Diagnose in 67 % bereits metastasiert
- offenbar keine ethnischen Unterschiede

**ANATOMIC SITES OF REGIONAL AND
DISTANT METASTASES OF
ADRENAL CORTICAL CARCINOMA**

Distribution of Metastases in 50 Autopsies at the National Institutes of Health	
Site	No. (%)
Liver	46 (92)
Lung	39 (78)
Retroperitoneum	24 (48)
Inferior vena cava	14 (28)
Serosa of intestine	11 (22)
Lymph nodes:	
Abdominal	16 (32)
Thoracic	13 (26)
Bone	9 (18)
Peritoneum	8 (16)
Kidney	6 (12)
Diaphragm	6 (12)
Heart	6 (12)
Spleen	4 (8)
Pancreas	4 (8)
Thyroid	3 (6)
Brain	2 (4)
Skin	1 (2)

STAGING OF ADRENAL CORTICAL CARCINOMA*

Percent	Stage	Staging Criteria
2.8	I T ₁ N ₀ M ₀	T ₁ Tumor less than or equal to 5 cm, no invasion
29.0	II T ₂ N ₀ M ₀	T ₂ Tumor greater than 5 cm, no invasion
19.3	III T ₁ N ₁ M ₀ T ₂ N ₁ M ₀ T ₃ N ₀ M ₀	T ₃ Tumor any size, locally invasive but not involving adjacent organs T ₄ Tumor of any size with invasion of adjacent organs
48.9	IV Any T, any N, M ₁ T ₃ , N ₁ T ₄	N ₀ Negative regional node N ₁ Positive regional nodes M ₀ No distant metastases M ₁ Distant metastases