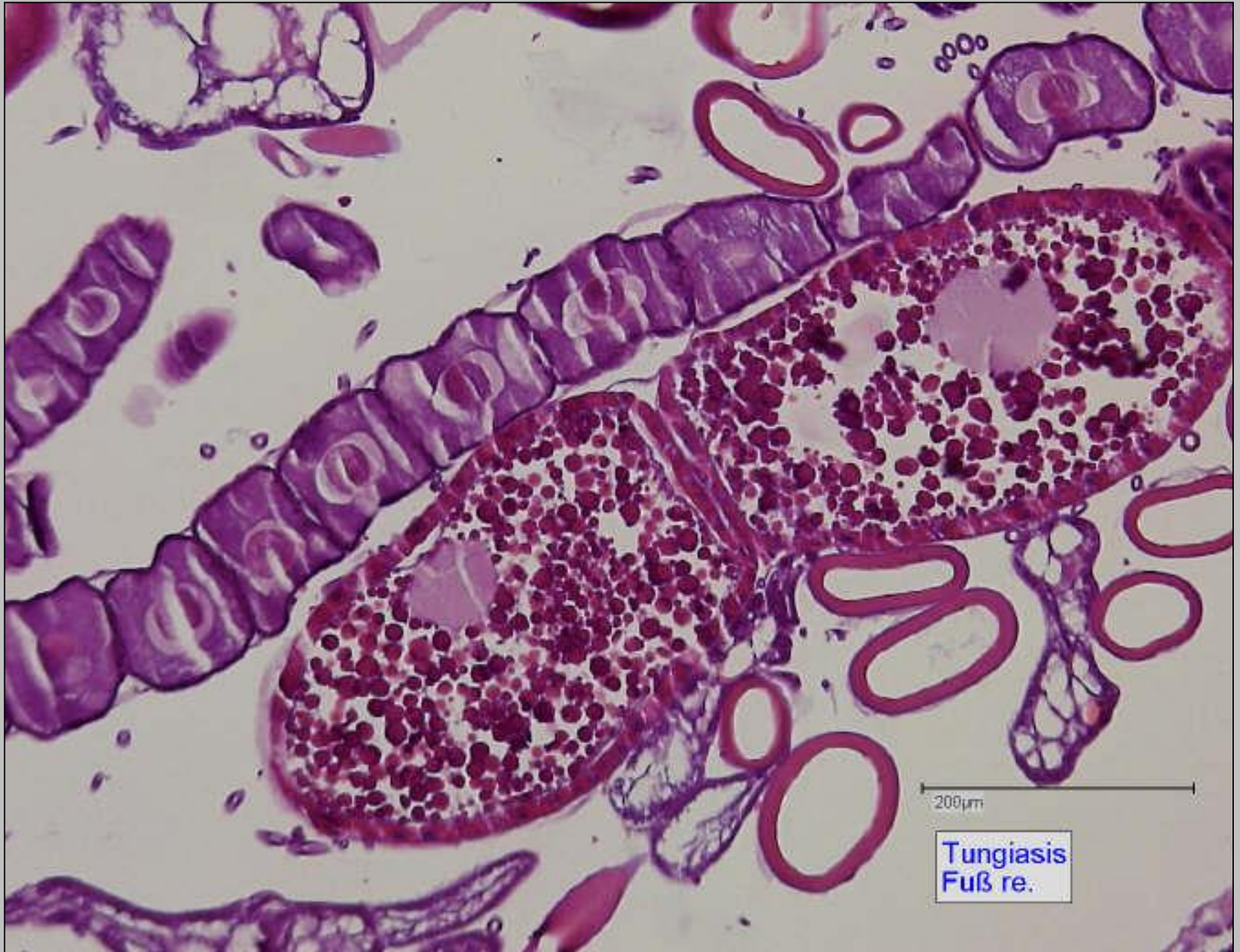

Bilder einer Tungiasis


- Patient: männlich 1955
- Vorgeschichte: Aufenthalt in Sansibar vor ca. 5 - 6 Wochen
- Symptome: Tungiasis
 - Fuß rechts plantar ein solitärer Knoten

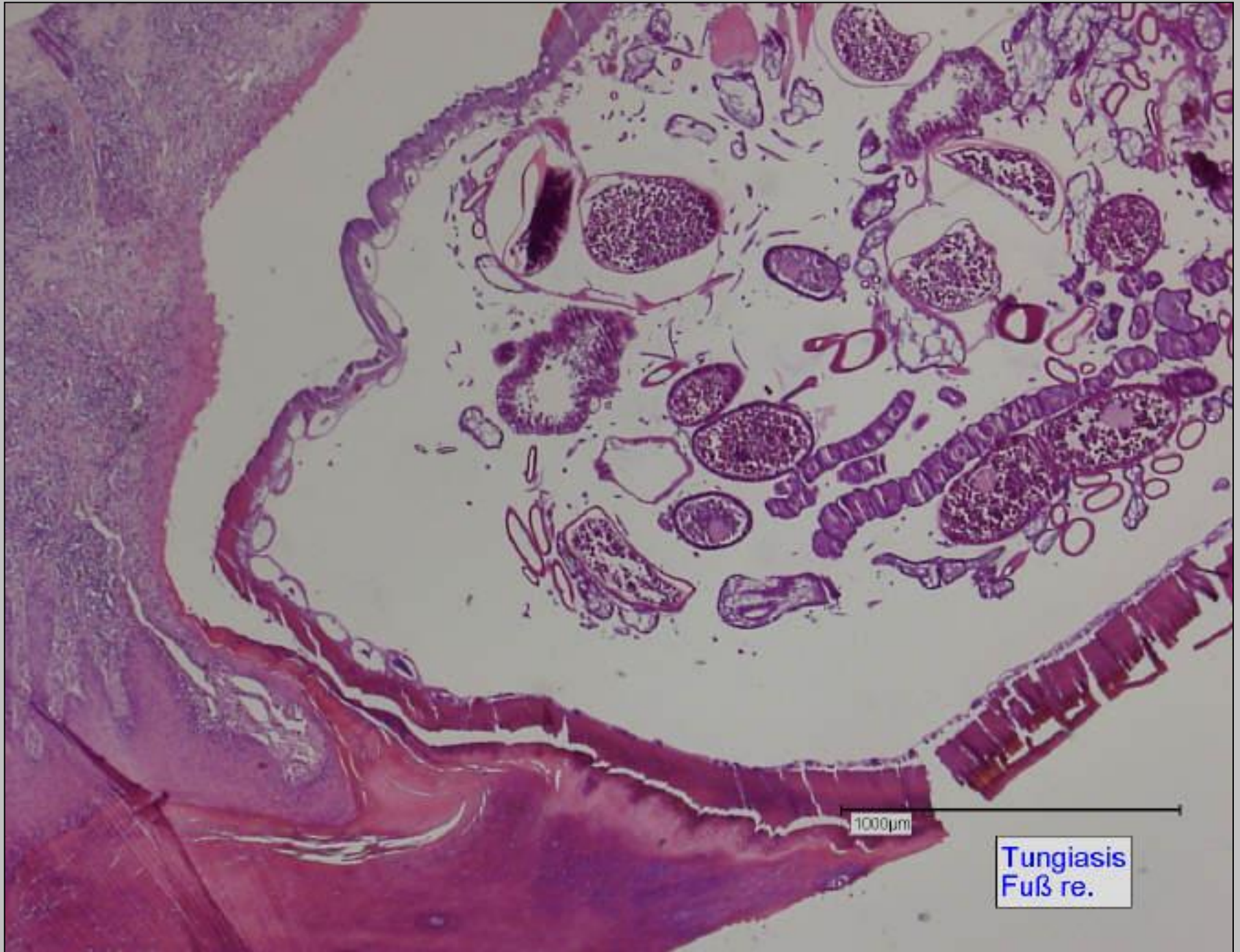




200µm

Tungiasis
Fuß re.

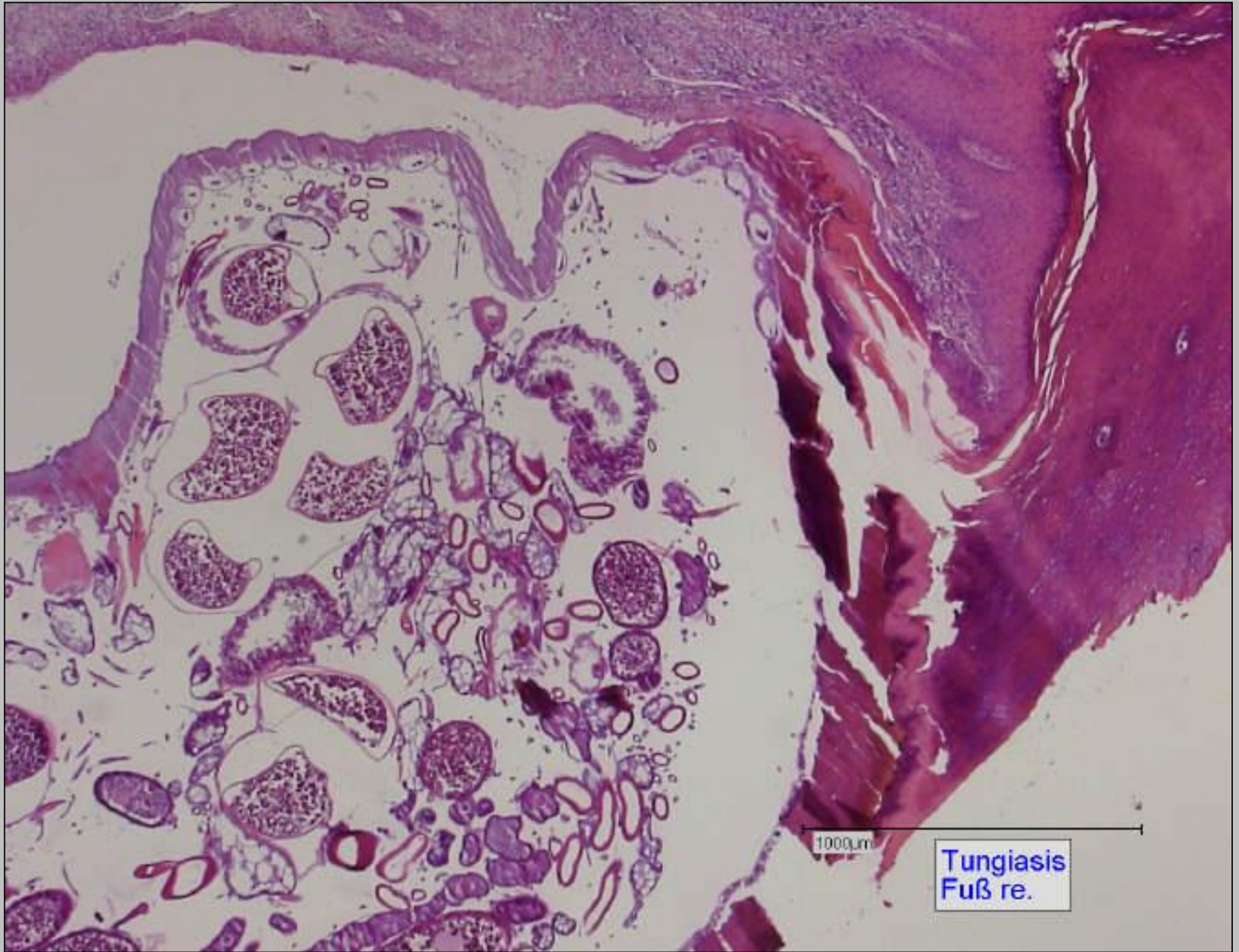




1000μm

Tungiasis
Fuß re.

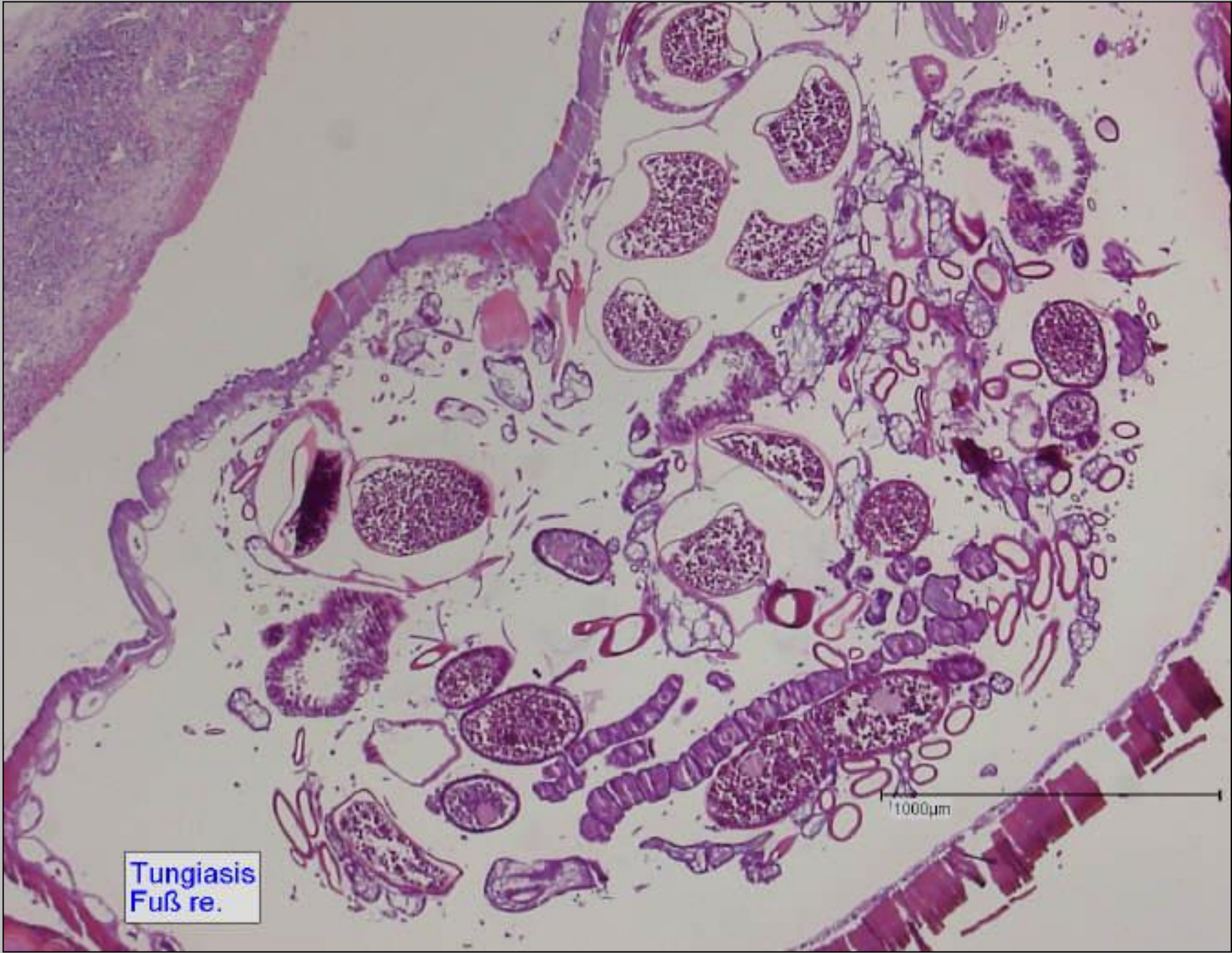




100µm

Tungiasis
Fuß re.





Tungiasis
Fuß re.

1000µm

