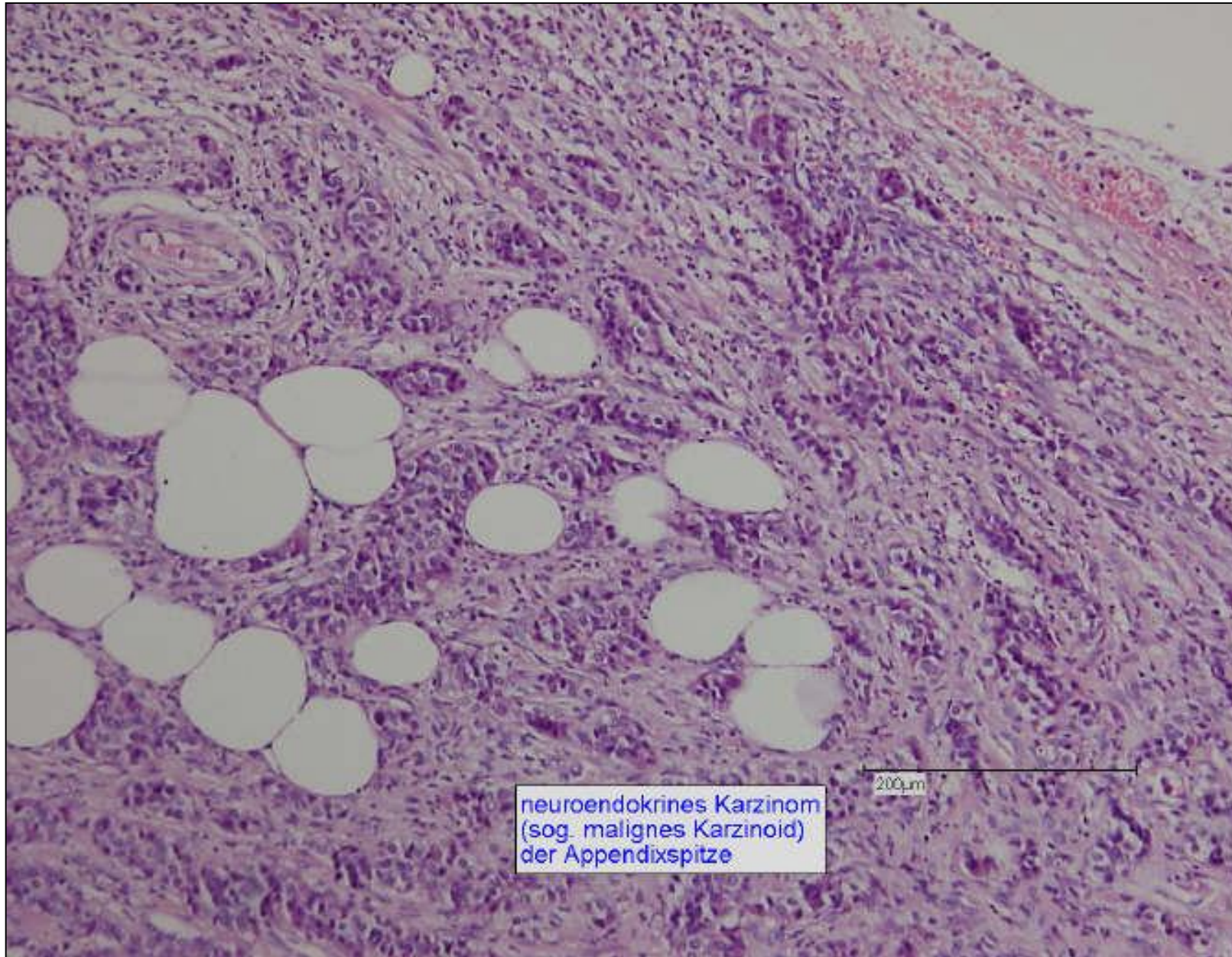
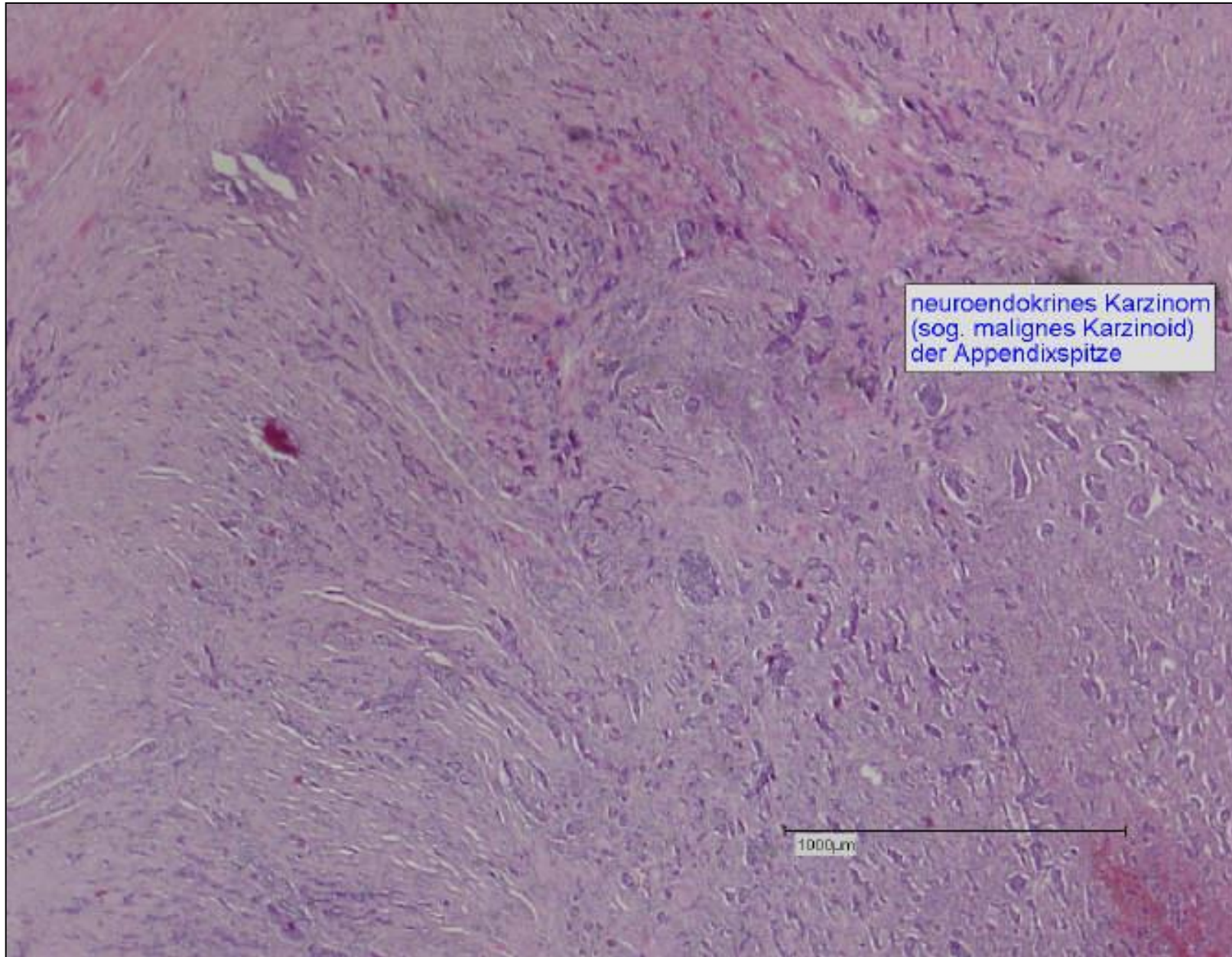


Neuroendokrines Karzinom der Appendixspitze

Falldemonstration
weiblich 53 Jahre alt

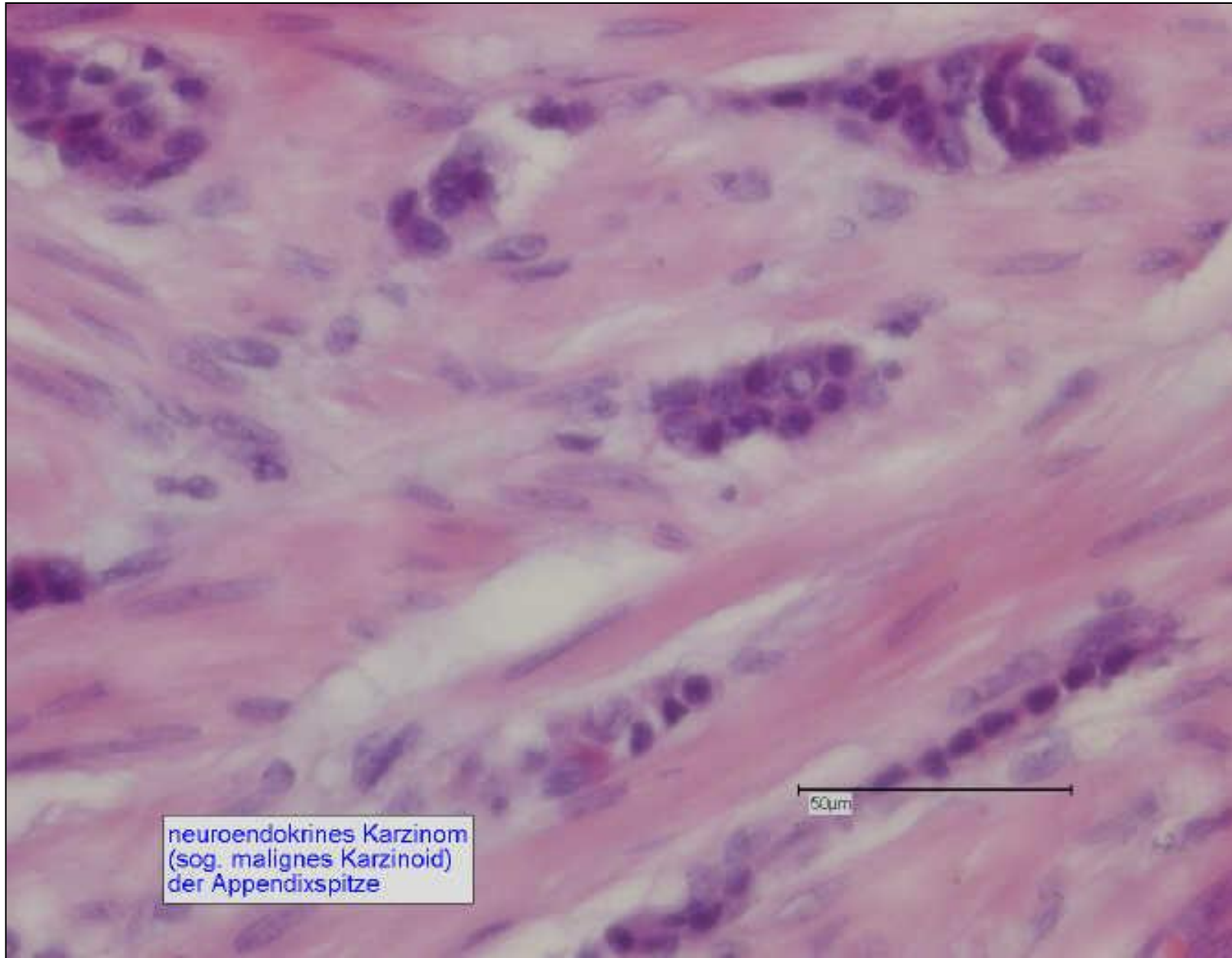




neuroendokrines Karzinom
(sog. malignes Karzinoid)
der Appendixspitze

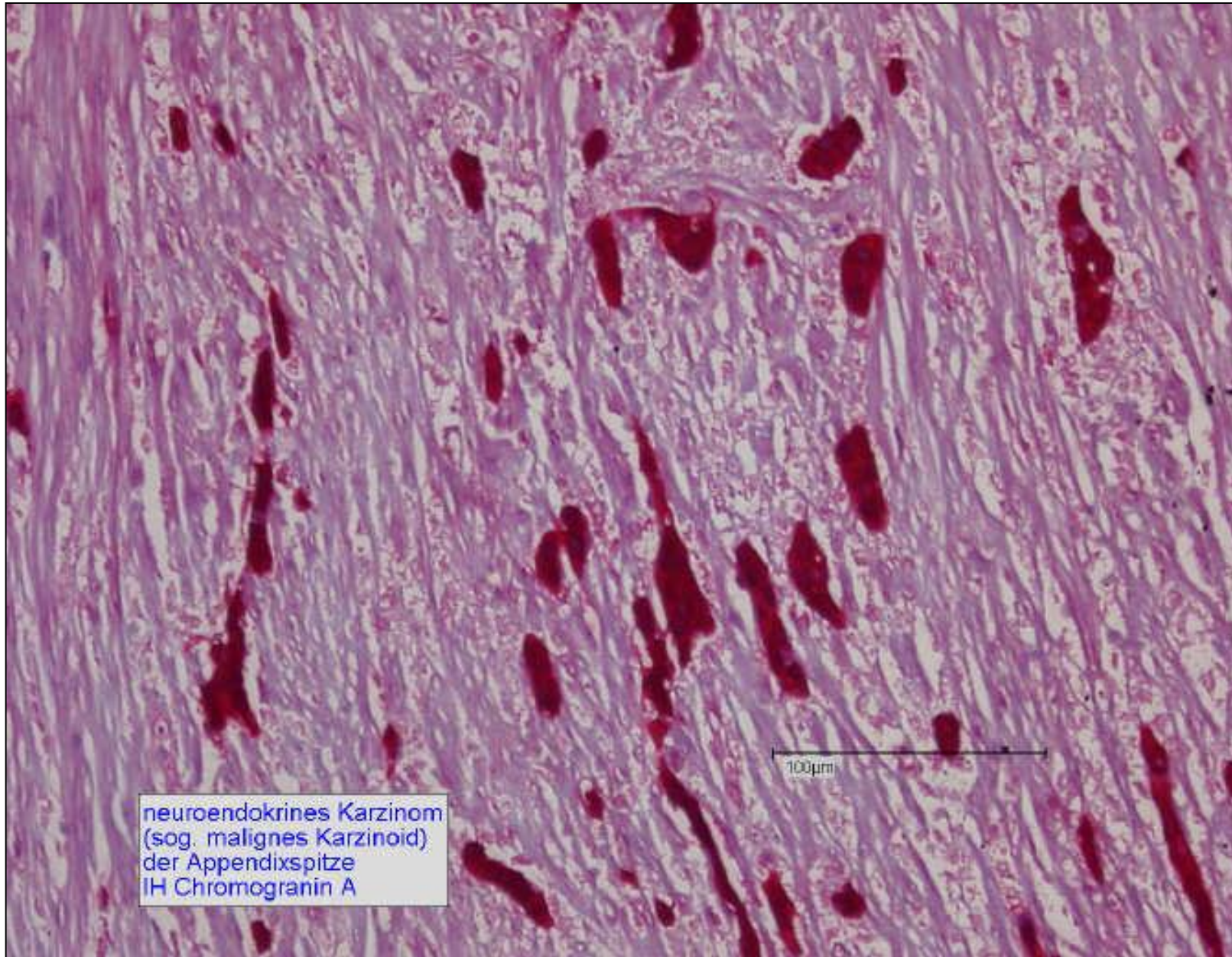
100µm





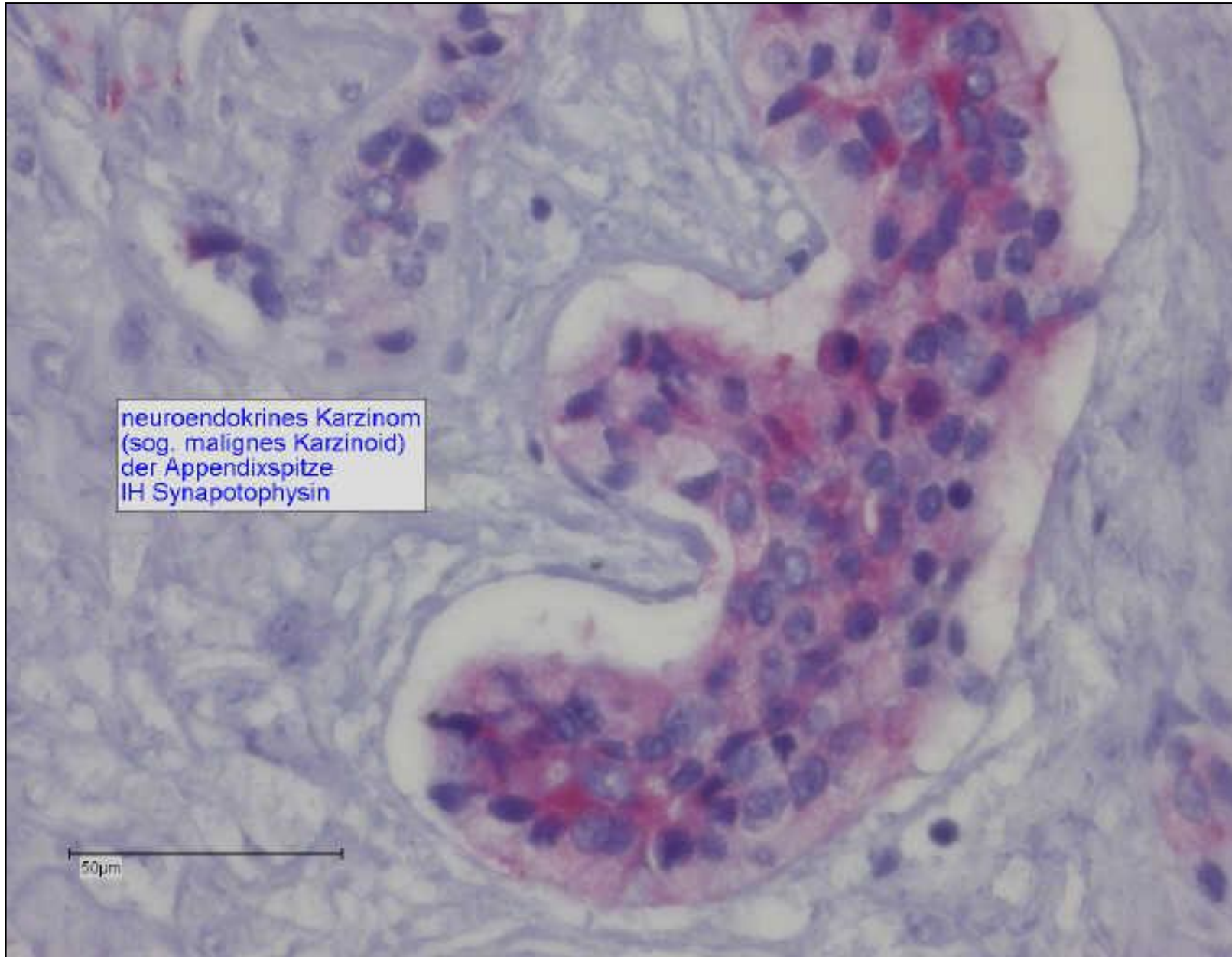
neuroendokrines Karzinom
(sog. malignes Karzinoid)
der Appendixspitze





neuroendokrines Karzinom
(sog. malignes Karzinoid)
der Appendixspitze
IHC Chromogranin A





neuroendokrines Karzinom
(sog. malignes Karzinoid)
der Appendixspitze
IH Synapotophysin

50µm

