
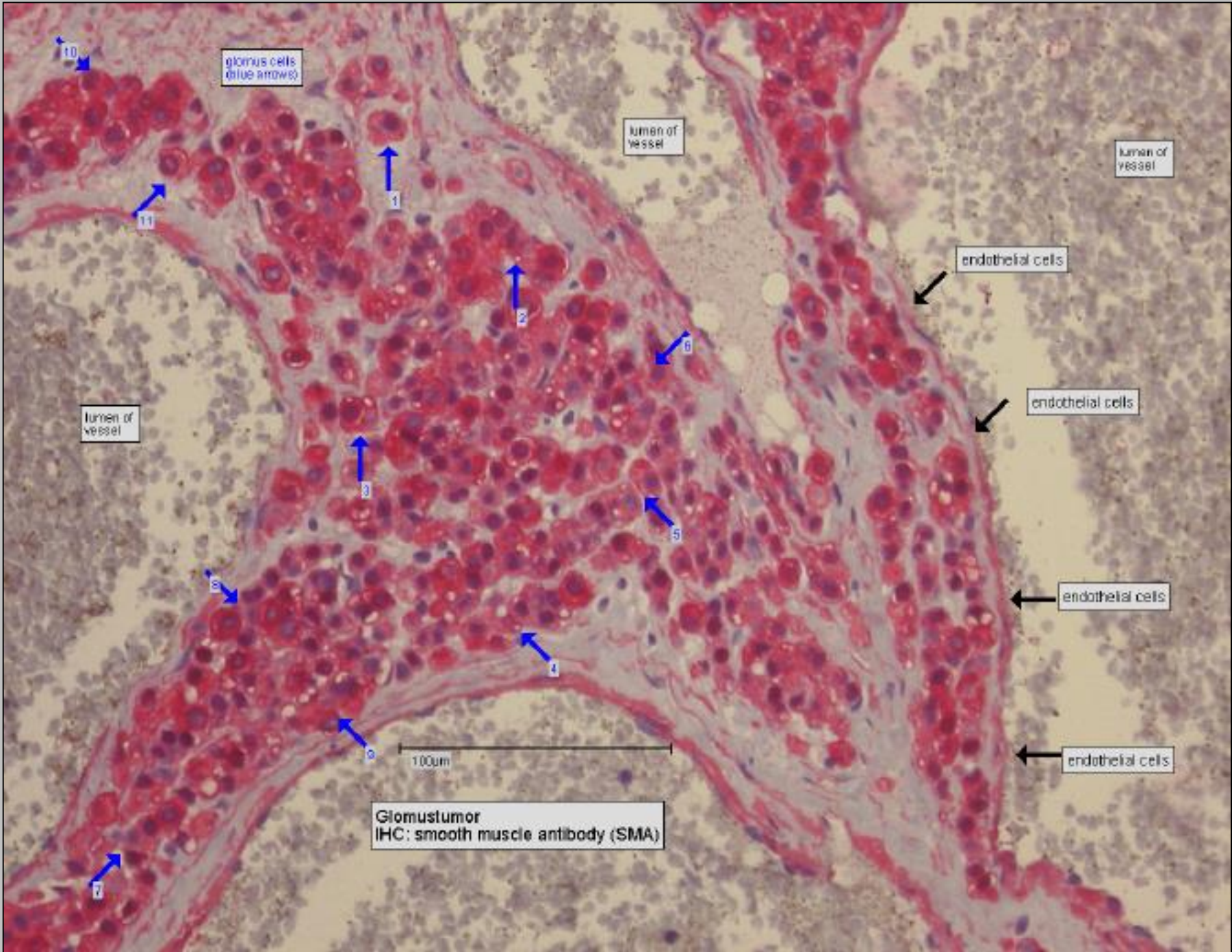
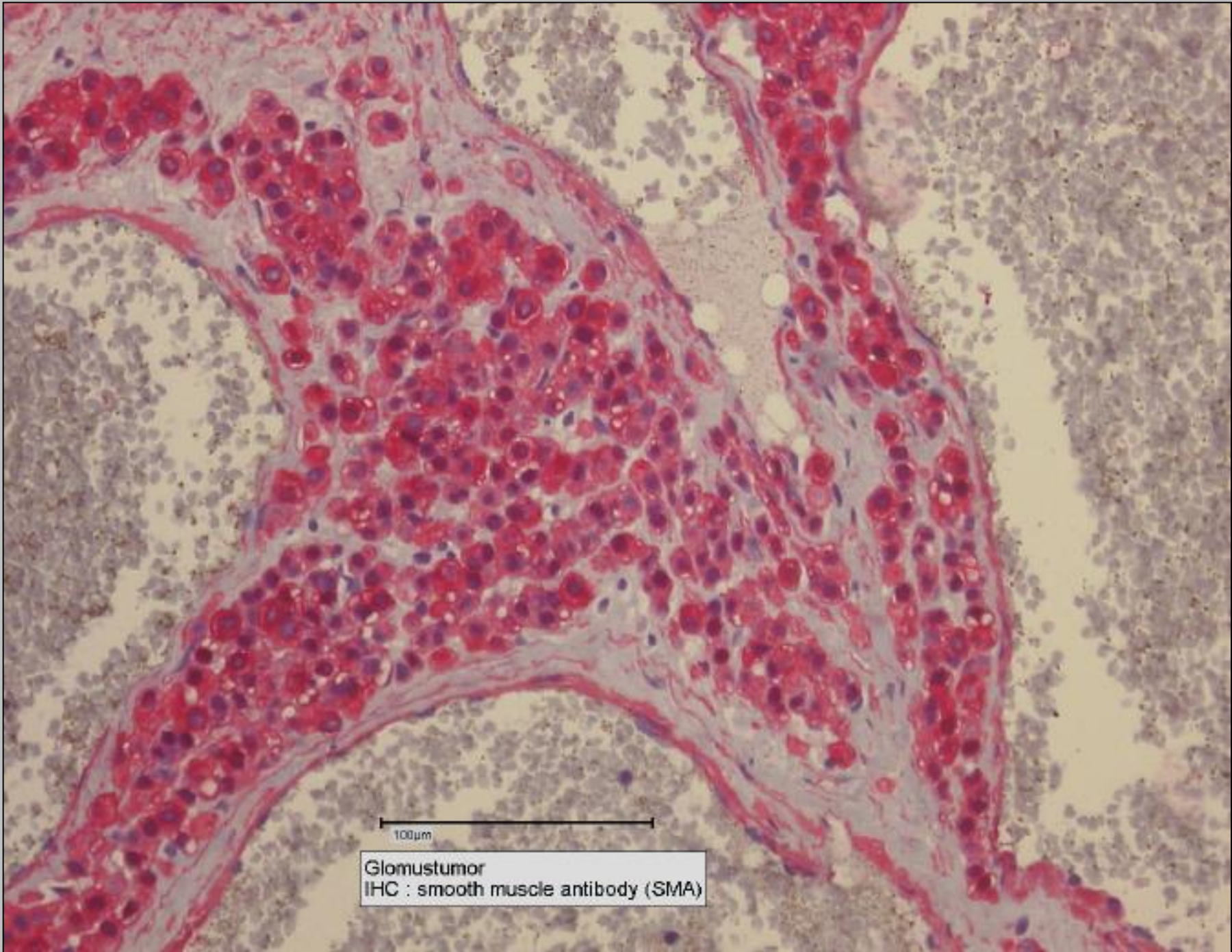


Glomustumor

- Patient: männlich geboren 1940
- Vorgeschichte: Exzidat aus Unterarm links, V.a. Weichteiltumor
- Makroskopisch: zwei 1g schwere Weichteilexzidate mit einem 8mm großen dunkelbraun-rötlichen Knoten




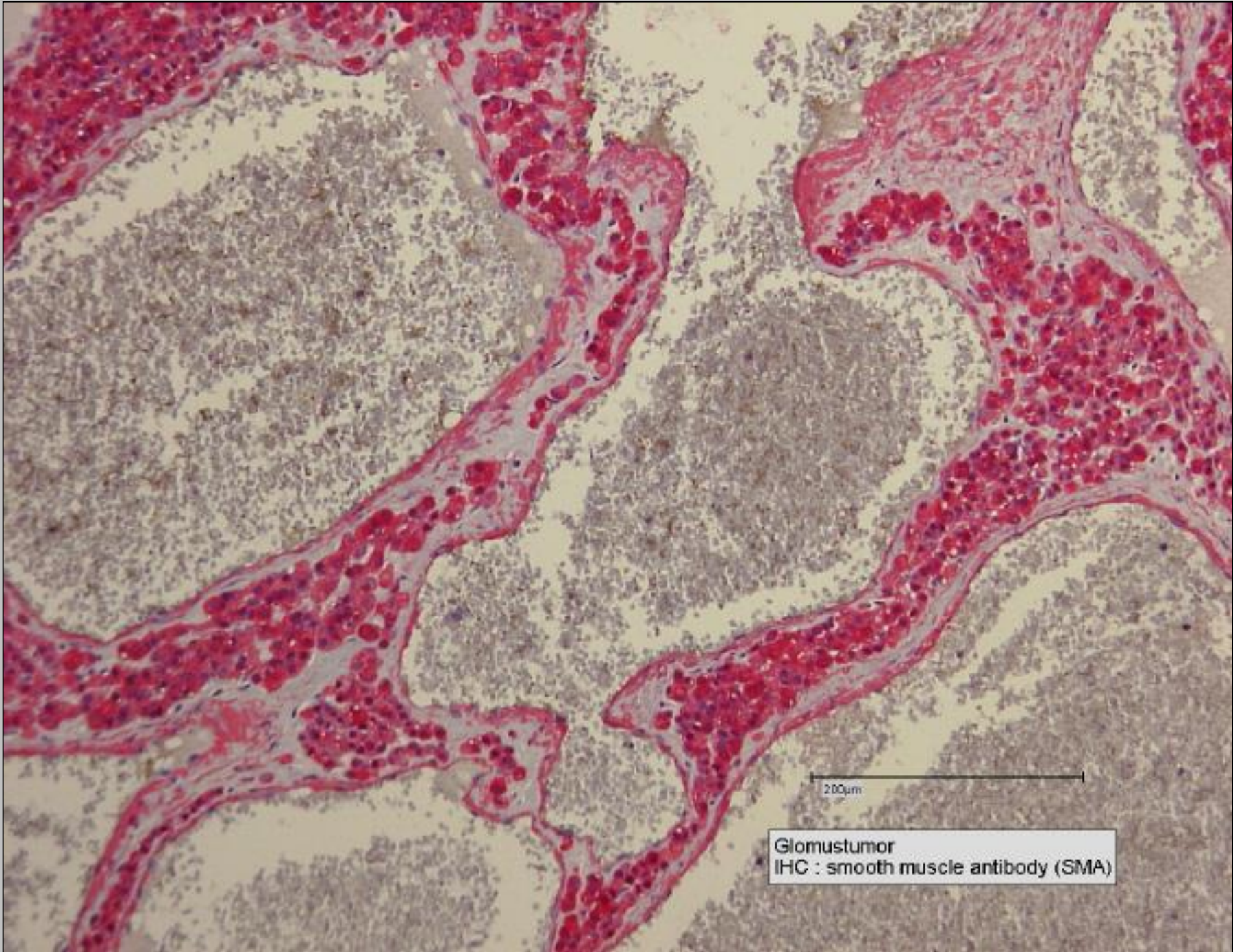




100µm

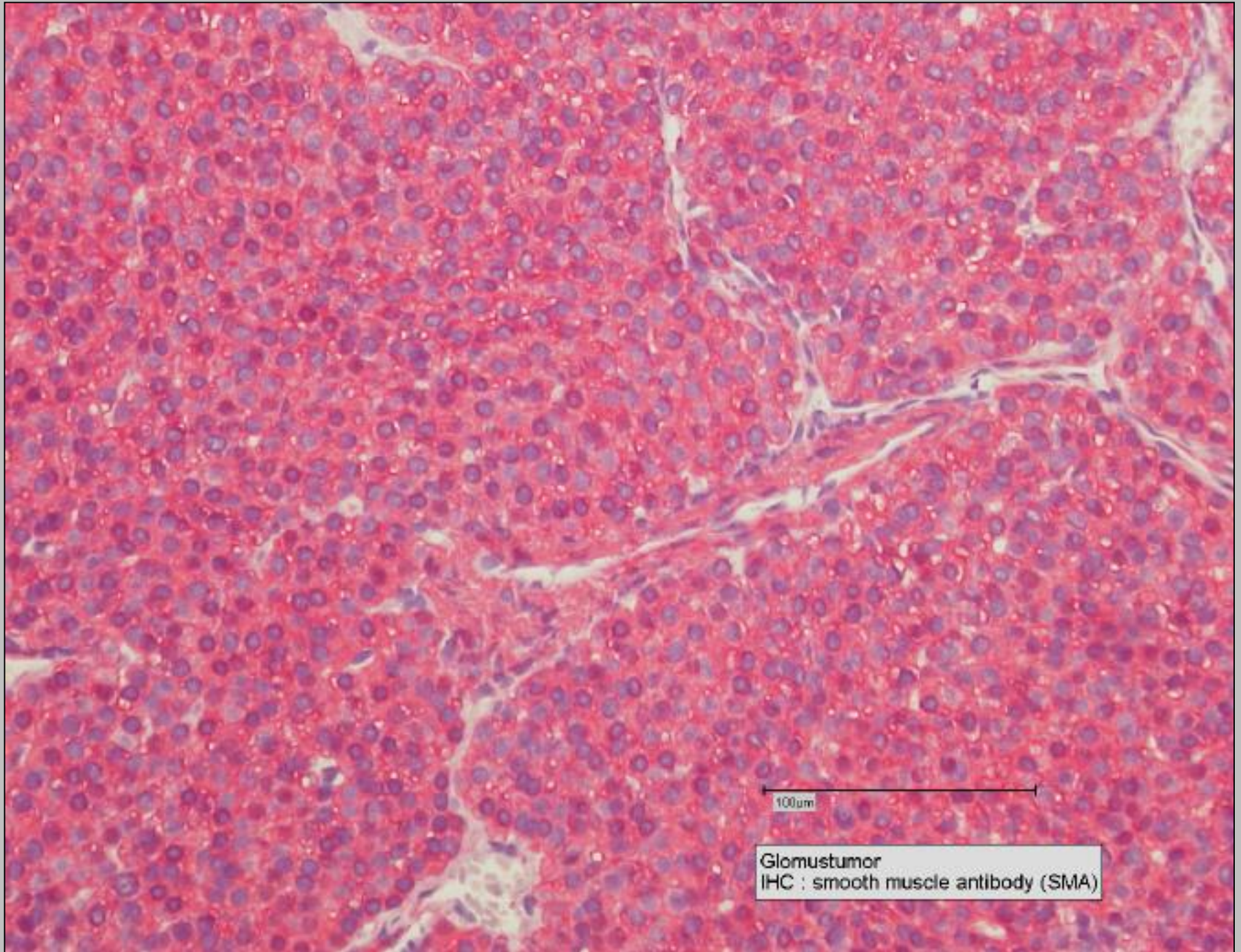
Glomustumor
IHC : smooth muscle antibody (SMA)






200um

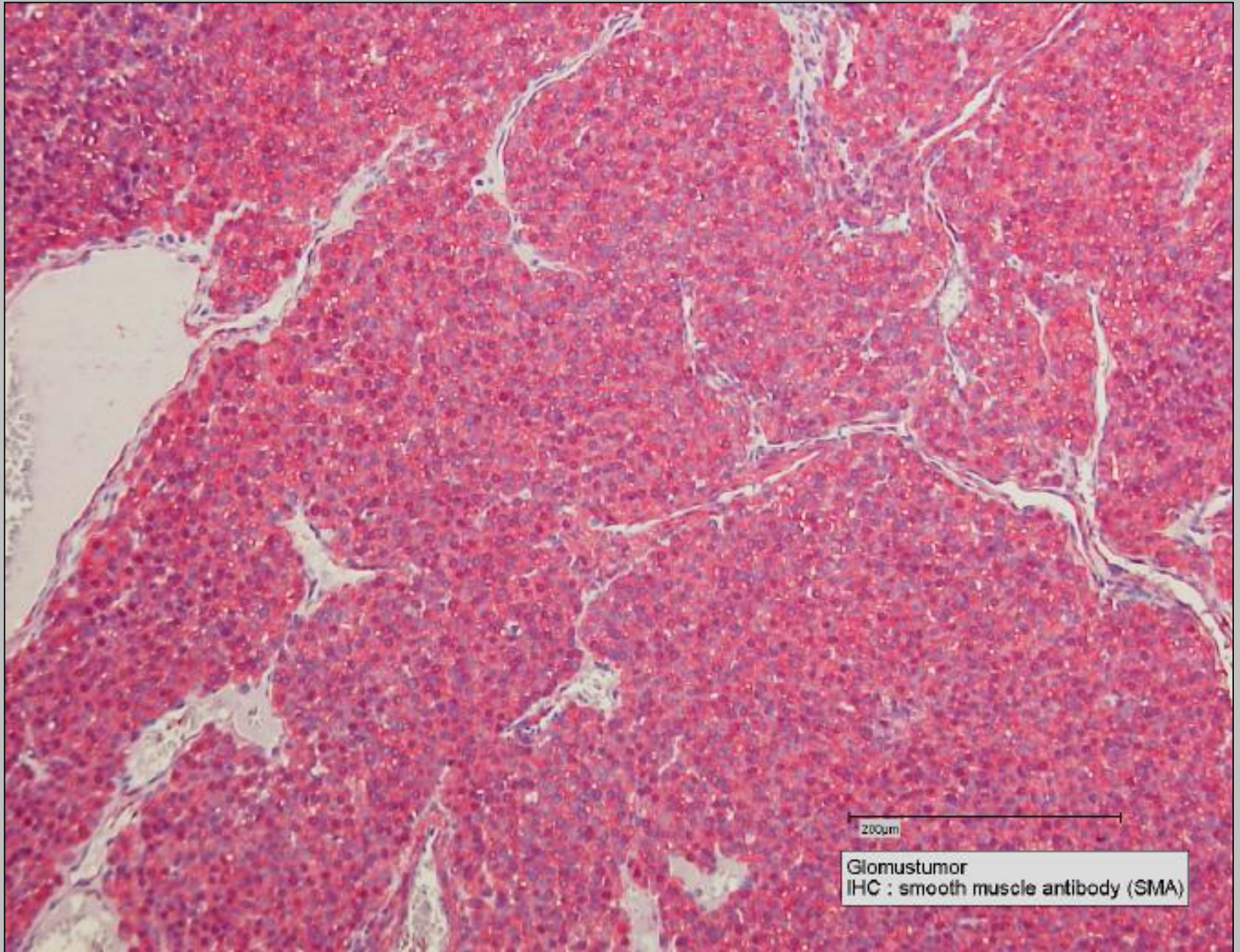
Glomustumor
IHC : smooth muscle antibody (SMA)



100µm


Glomustumor
IHC : smooth muscle antibody (SMA)


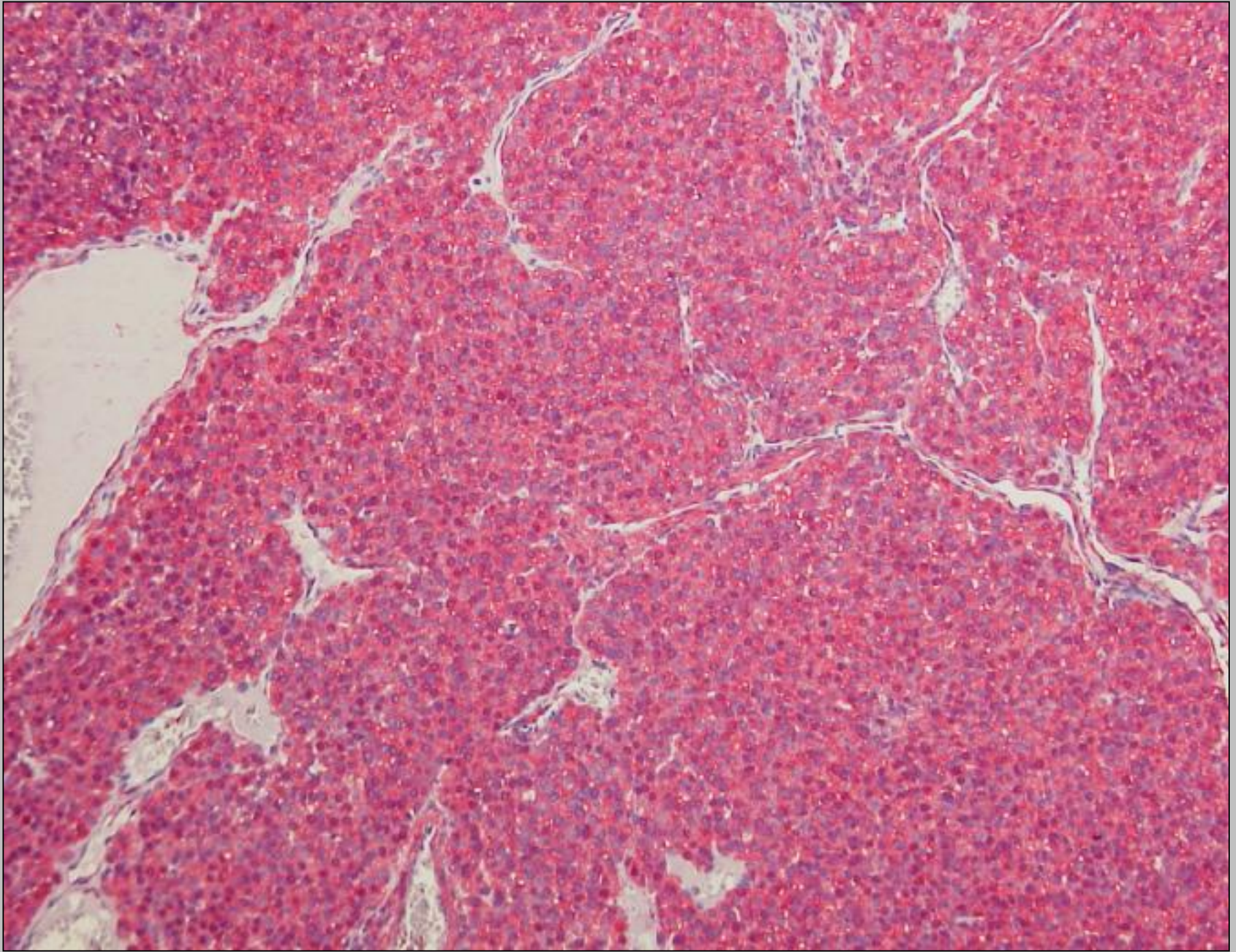


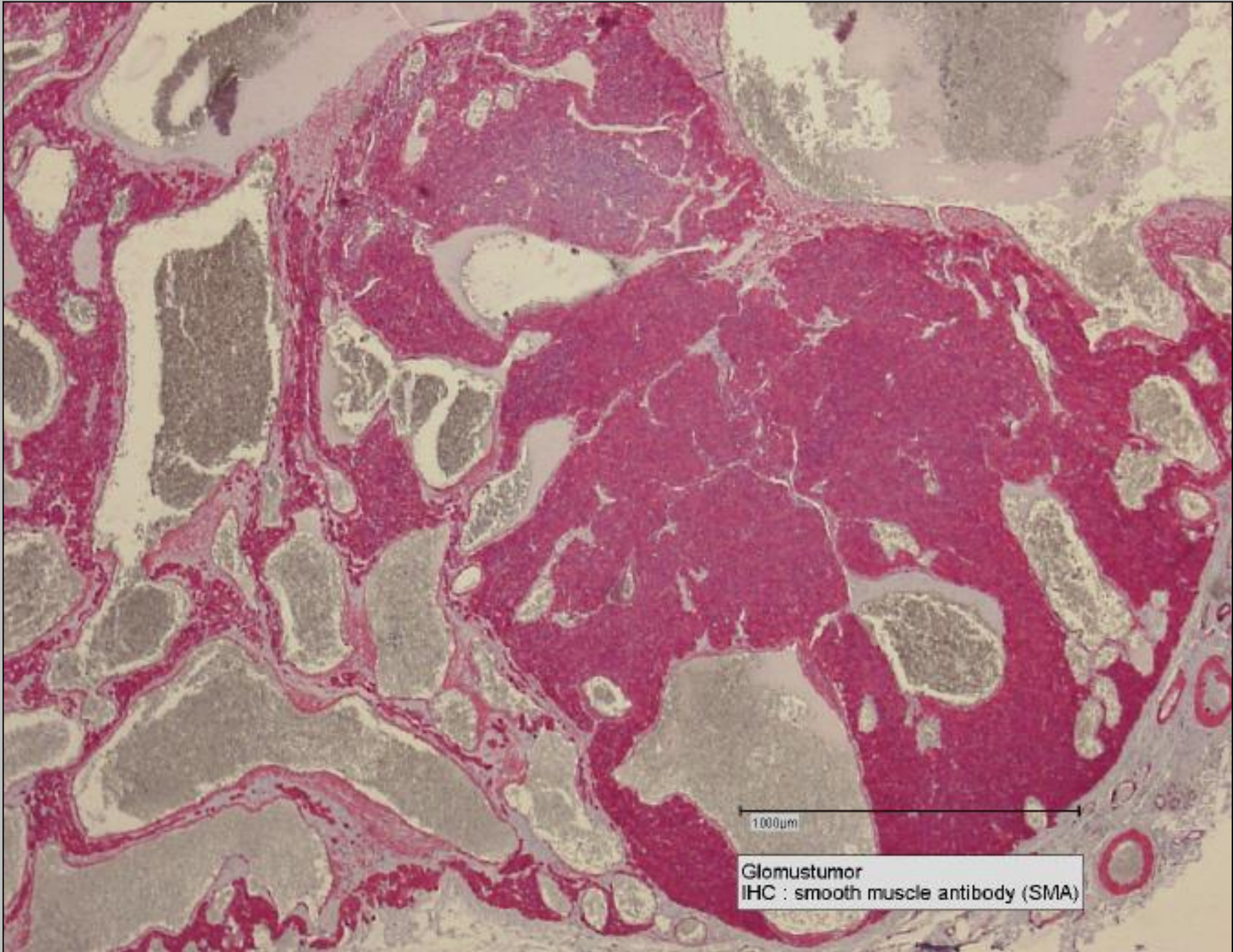


200µm

Glomustumor
IHC : smooth muscle antibody (SMA)




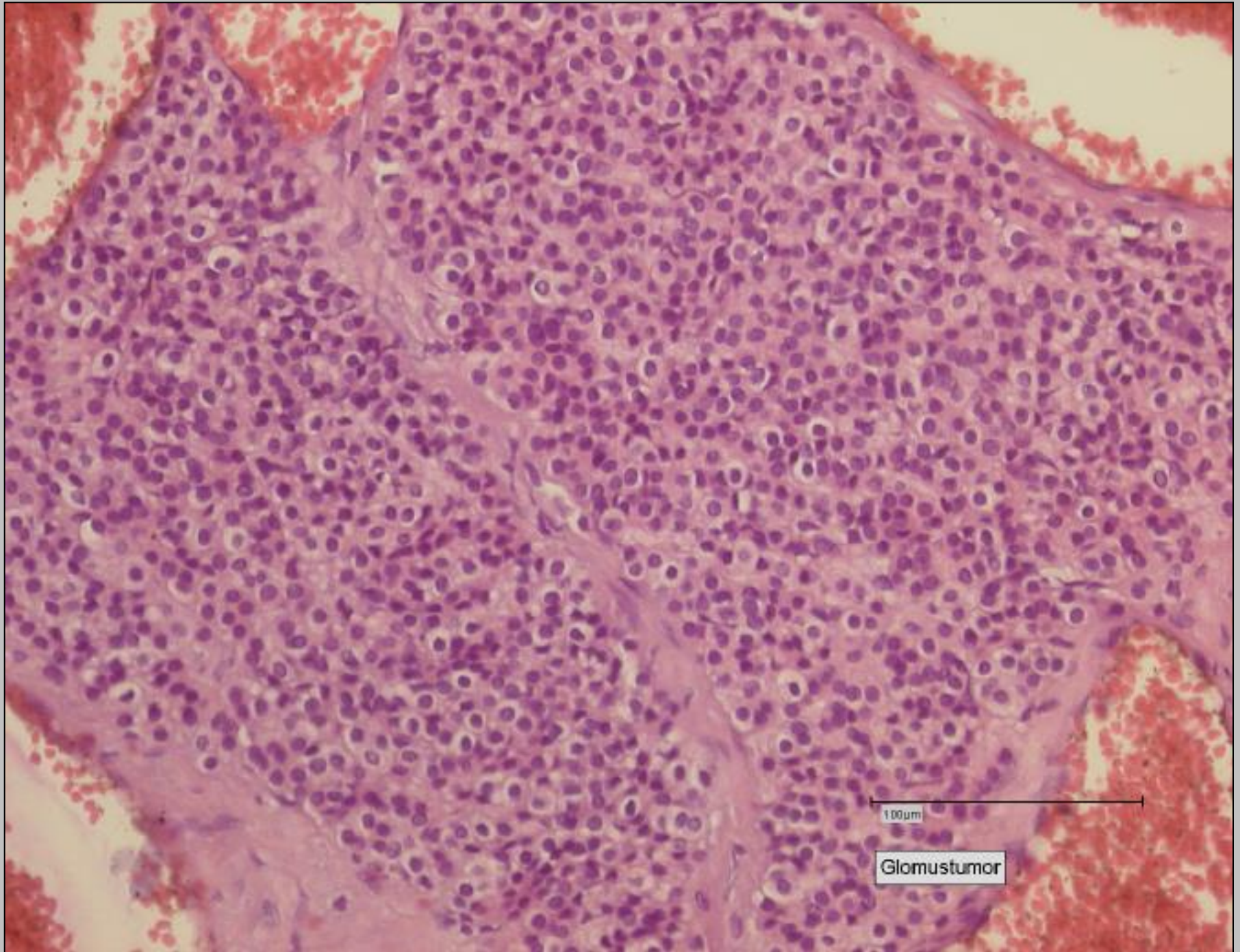



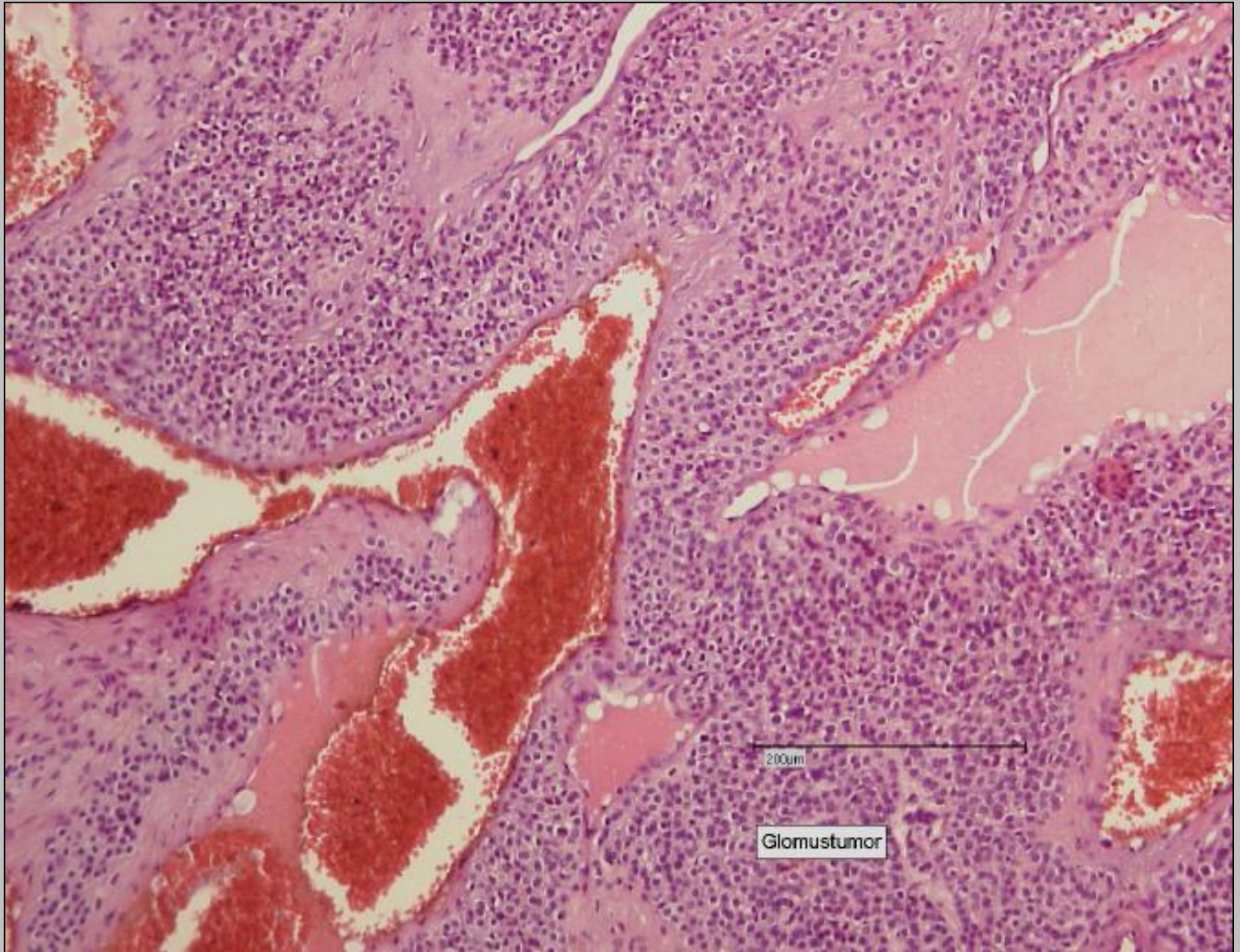


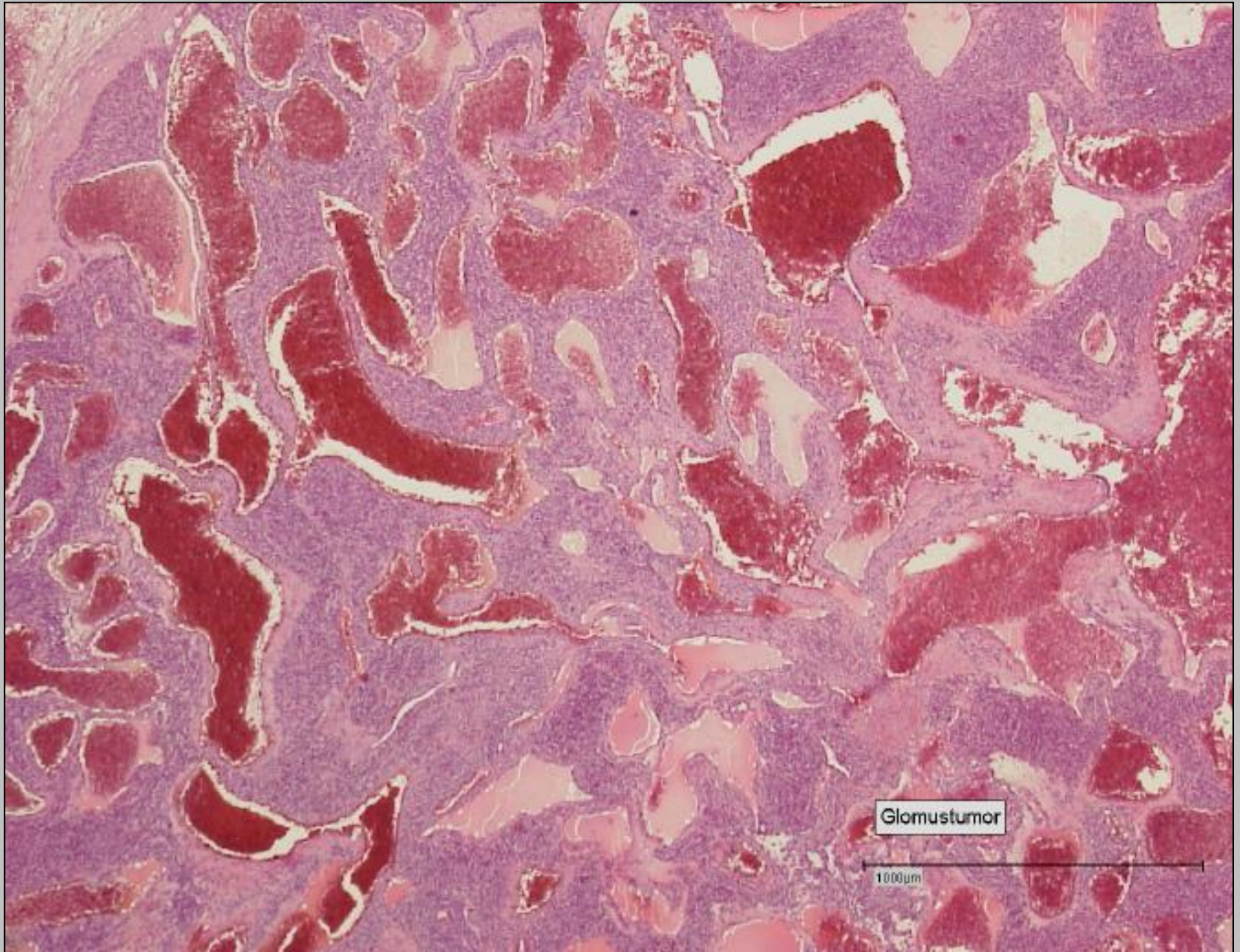
1000µm

Glomustumor
IHC : smooth muscle antibody (SMA)









Glomustumor

1000µm

